



PATIENT

Lilly Horaski

SPECIES

Canine

BREED

Shih Tzu

SEX

Female Spayed

AGE

14 years

WEIGHT

6.7kgs

INTERPRETED BY

Maggie Machen Lamy,
DVM, DACVIM
(Cardiology)

IMAGING PERFORMED BY

Nigel Gumley, DVM

HOSPITAL NAME

Cedarview Animal
Hospital

REFERRING VET

Dr. Gumley

INVOICE

31832

DATE

7/13/23

PRESENTING CLINICAL SIGNS

History: Grade 5/6 heart murmur audible on examination for dental consult. No clinical symptoms. BP: 185mmHg.

-Radiographs: Show mild LAE, otherwise no abnormalities.

ECHOCARDIOGRAM FINDINGS

2D, m-mode, color flow and doppler imaging is available. Mild diffuse thickening of mitral valve leaflets with mild prolapse into the left atrial lumen. Mild eccentric mitral regurgitation with normal left atrial dimension. Normal MR velocity. Normal LV diameter with adequate myocardial function. The tricuspid valve appears normal with trace tricuspid regurgitation. Normal velocity. Normal right atrial and ventricular diameter and morphology indicating no overt evidence of pulmonary arterial hypertension. The pulmonic and aortic valves are normal in morphology and mobility. Normal pulmonic and aortic outflow velocities with laminar flow. Trivial aortic and pulmonic insufficiency. No pericardial or pleural effusion noted. No obvious cardiac masses. A normal sinus rhythm was noted during the study (single lead ECG attached).

CARDIAC CHART

CANINE CARDIAC PARAMETERS	MR VMAX (m/s)	TR VMAX (m/s)	LA/AO (Boon method)	LA/AO (Heart Base; Swe)	FS (%)	EF (%)	EPSS (cm)
NORMAL PARAMETER	4.5-5.5	<2.7	1.3	<1.6	28-40	40-100	<0.6
PATIENT	5.6	2.0	NM	1.4	49	88	0.2
CANINE CARDIAC PARAMETERS	HR (BPM)	AV VMAX (m/s)	PV MAX (m/s)	BODY WEIGHT (kg)	LA 2D short axis Base view (cm)	LVIDd Avg; 2D and m-mode short axis (cm)	LVIDs Avg; 2D and m-mode short axis (cm)
NORMAL PARAMETER	50-100	0.7-1.7	0.7-1.6	BELOW	BELOW	BELOW	BELOW
PATIENT	120	1.2	0.6	6.7	2.3	3.5	1.8
*Normal chamber parameters expressed as a mean value (SD)				3	1.27 (5.3)	2.46 (2.46)	1.36 (5.5)
BODY WEIGHT DEPENDENT PARAMETERS				5	1.40 (4.5)	2.74 (5.2)	1.60 (4.7)
<i>*Note: All measurements based upon multi-modal images and methods. An average value is reported.</i>				10	1.50 (3.8)	3.27 (3.5)	2.06 (3.1)
				15	1.83 (2.0)	3.71 (2.4)	2.43 (2.1)
				20	2.02 (1.9)	4.14 (2.2)	2.80 (2.0)
				25	2.18 (2.4)	4.48 (2.9)	3.10 (2.5)
				30	2.33 (3.3)	4.83 (3.9)	3.39 (3.4)
				35	2.48 (4.3)	5.17 (5.0)	3.69 (4.5)
				40	2.62 (5.2)	5.48 (6.1)	3.96 (5.4)
				50	2.88 (7.1)	6.07 (8.3)	4.46 (7.4)

INTERPRETATION OF THE FINDINGS & FURTHER RECOMMENDATIONS

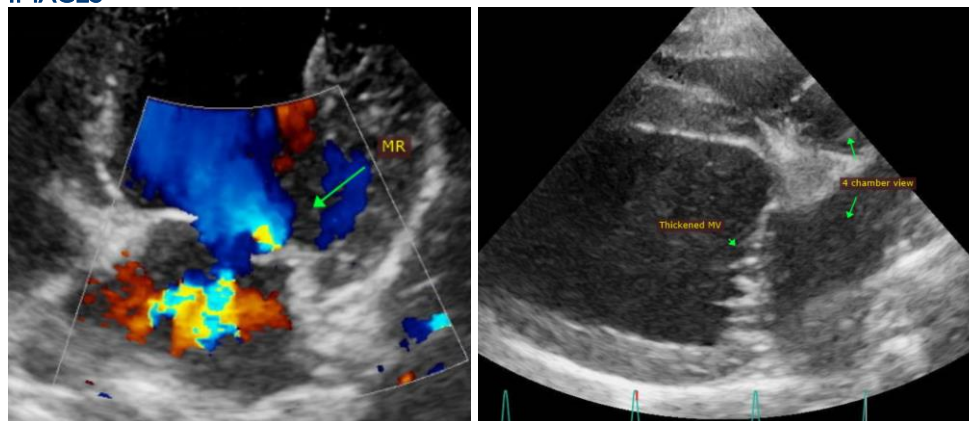
Chronic degenerative valve disease causing mild mitral and trace tricuspid regurgitation. Lack of significant left atrial enlargement indicates the current risk for complication is low. No concurrent issues such as systolic dysfunction or pulmonary hypertension are noted in this study.

In a dog with no significant left atrial enlargement, no cardiac medications are clearly indicated. Assessment of progression in the future will help predict long term prognosis, which is highly



PATIENT	variable at this stage. Omega fatty acid supplementation and mild salt restriction may be of some long-term benefit. Monitor for development of a cough, labored breathing, exercise intolerance or collapse episodes.
Lilly Horaski	
SPECIES	The reported blood pressure is elevated and should be reassessed for accuracy particularly given no reported clinical signs of severe hypertension (retinal changes, etc.) or evidence of LVH on echo. Ideally obtain serial measurements in a controlled, low stress environment and continue until 3 consecutive readings plateau within 5mmHg of variability. If persistently >180mmHg despite a relatively calm demeanor, recommend institution of amlodipine to effect. Additionally, if deemed accurate, screening for predisposing underlying causes of SHT is recommended (Cushing's, PLN, adrenal tumor, etc.), as primary disease is relatively uncommon and a rule out diagnosis.
Canine	
BREED	
Shih Tzu	
SEX	Anesthetic risk is considered mild if needed. Cardiac protective drug choices (opioid/benzodiazepine premedication, propofol or alfaxalone induction, isoflurane gas) are recommended. Pre-oxygenate for 5-10 minutes prior to induction. Monitor for arrhythmias, hypotension, and hypoxia both intra and post-operatively and intervene as necessary. Mild IV fluid restriction is recommended to avoid fluid overload. Avoid heart rate stimulating drugs such as atropine unless clinically indicated.
Female Spayed	
AGE	
14 years	
WEIGHT	Recommend conservative monitoring with a recheck echocardiogram in 6 months, sooner if any development of clinical signs.
6.7kgs	

IMAGES



INTERPRETED BY

Maggie Machen Lamy,
DVM, DACVIM
(Cardiology)

IMAGING PERFORMED BY

Nigel Gumley, DVM

HOSPITAL NAME

Cedarview Animal
Hospital

REFERRING VET

Dr. Gumley

INVOICE

31832

DATE

7/13/23

The information and recommendations provided are based on the images presented by the referring veterinarian. No evaluation can be communicated regarding pathology that was not visible in the image/video clips provided.

Thank you for this referral. This report was generated using transcription software, and minor dictation errors may be present. If the clinical or image interpretation does not parallel your findings or if I can be of any further assistance, please contact me.

Maggie Machen Lamy, DVM
Diplomate of the American College of Veterinary Internal Medicine (Cardiology)
info@sonopath.com